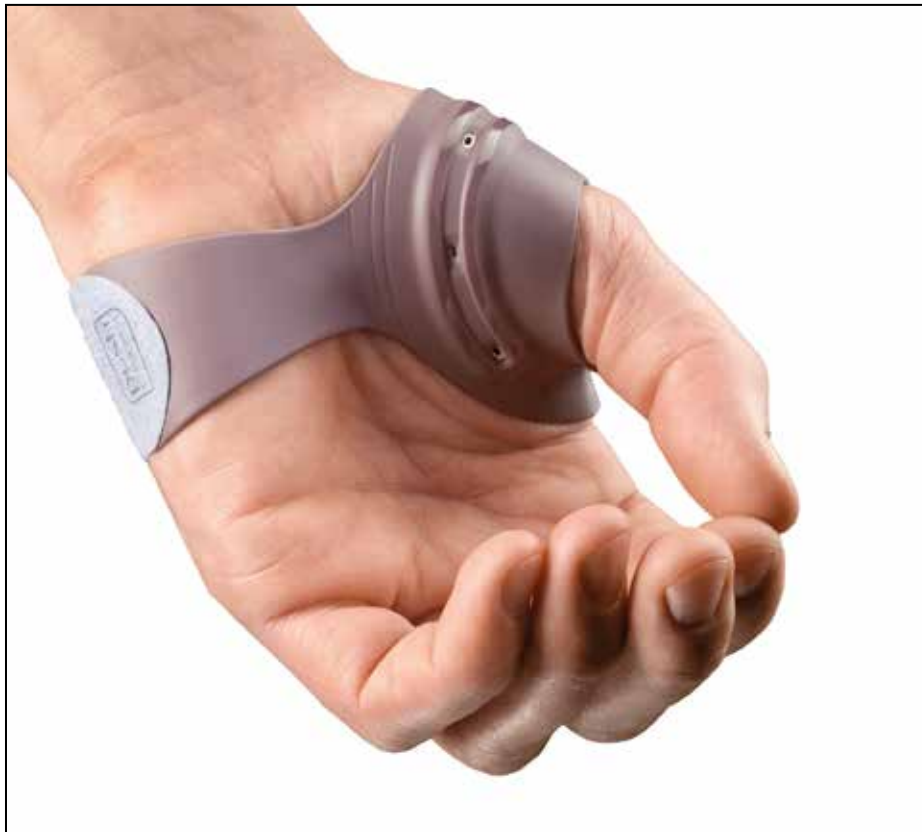

The Push ortho Thumb Brace CMC



A White Paper

Describing the Stabilizing Mechanism of the Push ortho Thumb Brace CMC



The Push ortho Thumb Brace CMC

To the reader:

- The terms *brace*, *splint*, and *orthosis* are synonymous; the term *brace* is used in this paper.
- The joint at the base of the thumb has multiple names: 1) *carpometacarpal* or *CMC joint*, 2) *basal joint*, 3) *trapezialmetacarpal* or *TM joint*, and 4) *trapeziometacarpal joint* or *TMJ*. The term *CMC joint* is used in this paper.

THUMB CMC OSTEOARTHRITIS

Osteoarthritis of the joint at the base of the thumb, the carpometacarpal (CMC) joint, commonly causes pain during hand use (Figure 1). Those with osteoarthritis of the thumb CMC joint complain of pain with resisted thumb motions and particularly with forceful pinching. This pain creates difficulty with everyday tasks

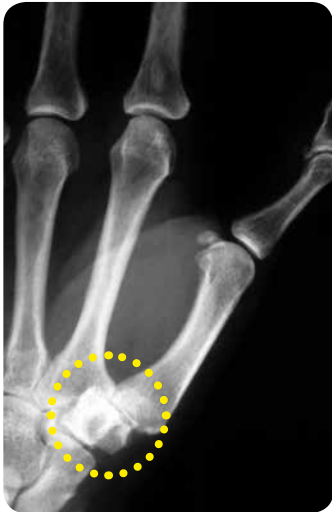

Figure 1: X-ray view of a right thumb with osteoarthritis of the thumb CMC joint (circle).

such as twisting open a jar lid, turning a key in a lock, turning doorknobs, sustained pinching or writing, picking up a large book, holding a cup of tea/coffee, doing needlework or other hand crafts, carrying a heavy object, playing golf and/or playing tennis and using scissors, etc.¹⁻⁴

Twenty-five to forty percent of individuals over the age of fifty-five have radiographic evidence of thumb carpometacarpal (CMC) osteoarthritis (OA) with females having a greater incidence than males.^{1,5,6} Approximately one in four women and one in twelve men in

older age groups have osteoarthritis of this essential base joint.^{2,3,7-12}

In the United States 18.2 percent of adults over sixty years of age have palpable first CMC joint deformity.¹² Additionally, the thumb CMC joint ranks as the most common site of upper extremity surgery related to osteoarthritis.^{1,2,5,11} Furthermore, levels of pain and disability are significantly higher among patients with thumb CMC OA than those without.¹³

Pain creates difficulty with everyday tasks.

Additional information regarding the prevalence and impact of thumb CMC osteoarthritis is provided in the text.

DEVELOPMENT OF THUMB CMC OA

The human thumb CMC joint exhibits a large range of motion (Figure 2). This extensive mobility is enabled by the inherent laxity of the joint ligament configuration. When thumb CMC joint osteoarthritis develops, the ligaments supporting the joint become insufficient and pathological motion develops.

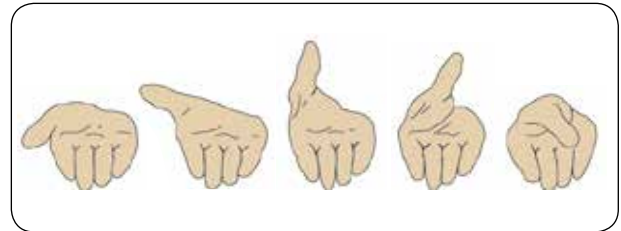


Figure 2: The range of motion of the thumb CMC joint from a position of full extension (left) to full flexion (right).

The pull of the strongest thumb muscles against inadequate ligaments results in the most common pathological motion at the CMC joint: *dorsal translation*. Dorsal translation is the movement of the first metacarpal base sliding on the stationary trapezium toward the dorsum (top) of the thumb (Figure 3).

Dorsal translation occurs when the thenar muscles contract: the thumb metacarpal tilts; the distal end of the bone moves toward the palm and the proximal end moves dorsally (Figure 3C). It is believed that this shift of motion, even slight, creates pain.

As osteoarthritis progresses, the innately slack capsule and ligaments of the thumb CMC joint become excessively loose. Ultimately the ligaments entirely lose their ability to restrain the dorsal translation of the metacarpal on the trapezium.¹¹ In the early stages of thumb CMC osteoarthritis dorsal translation represents a small shift in joint alignment. As osteoarthritis progresses, the metacarpal base moves further and further dorsally, and may even dislocate relative to the trapezium.¹¹

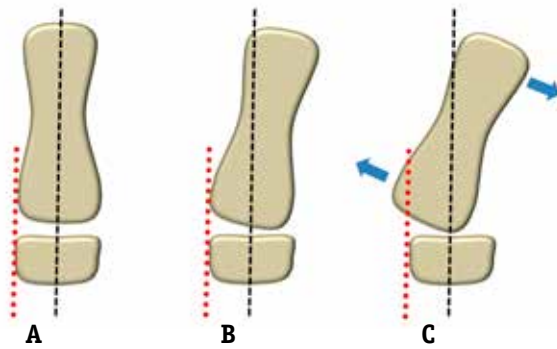


Figure 3: This schematic drawing of a left thumb illustrates the movement of the thumb metacarpal on the trapezium (red dotted line is the dorsum of the thumb). A) Normal thumb CMC joint at rest with the metacarpal and the trapezium in alignment. B) Normal thumb CMC joint flexion; note the bones remain in alignment and C) Thumb CMC joint with osteoarthritis where the first metacarpal base moves out of alignment in the dorsal direction (dorsal translation) while the metacarpal head flexes forward.

USE OF BRACING IN CMC OSTEOARTHRITIS

Bracing of the osteoarthritic thumb CMC joint is standard non-surgical care for pain relief.^{1,2,5,9,13-25} In a Scandinavian study, after seven months seventy percent of patients no longer required surgical intervention when bracing was combined with activity modification and non-steroid anti-inflammatory medication.¹⁸ At one year, those given braces (worn day and night) together with heat, home exercises, and instruction in joint protection reported significantly decreased stiffness and pain along with improved function compared to a control group given only joint protection instruction.¹⁷

Bracing of the osteoarthritic thumb CMC joint is standard non-surgical care for pain relief.

Both the National Collaborating Centre for Chronic Conditions in the United Kingdom and the evidence-based European League against Rheumatism (EULAR) recommend bracing as part of thumb CMC osteoarthritis treatment.^{16,26} Although

there is consistent evidence that thumb CMC bracing reduces pain, there is not yet evidence of a single superior brace design.^{13,27}

Numerous studies have investigated the effect of bracing on pain and function but none include a definition of the primary kinematic function of the brace. In other words, apart from general immobilization of the thumb CMC joint, there is no explanation of the precise mechanism by which the brace design achieves pain reduction or increased function.¹³

CUSTOMARY BRACE DESIGN FOR THUMB CMC OA

The goal of most thumb CMC joint braces is to prevent movement at the thumb CMC joint by immobilizing the joint. To accomplish immobilization of the thumb CMC joint, most braces also incorporate the adjacent wrist joint and/or the thumb metacarpophalangeal (MP) joint^{1-3,14,17,23} (Figure 4). Frequently the degree of immobilization imposed by these braces interferes with daily tasks to such an extent that wearing compliance becomes an issue.

The challenge of treating thumb CMC joint osteoarthritis is to balance the opposing goals of providing stability to the thumb CMC joint while also allowing mobility of the joint.²⁸ Achieving these contradictory goals are the challenge for any thumb CMC joint brace design. The optimal brace would relieve the pain at the CMC joint while continuing to allow maximal functional use of the thumb.

IMMOBILIZATION OR STABILIZATION?

Immobilization seeks to decrease inflammation by providing periods of rest to the joint. The role of inflammation in osteoarthritis remains controversial,²⁹ bringing into question whether immobilization in a brace is the optimal treatment approach for thumb CMC osteoarthritis.

It is well known, however, that prolonged immobilization decreases muscle strength, which in turn decreases joint stability.²¹ If immobilization is the chosen treatment for thumb CMC OA, the resulting decrease

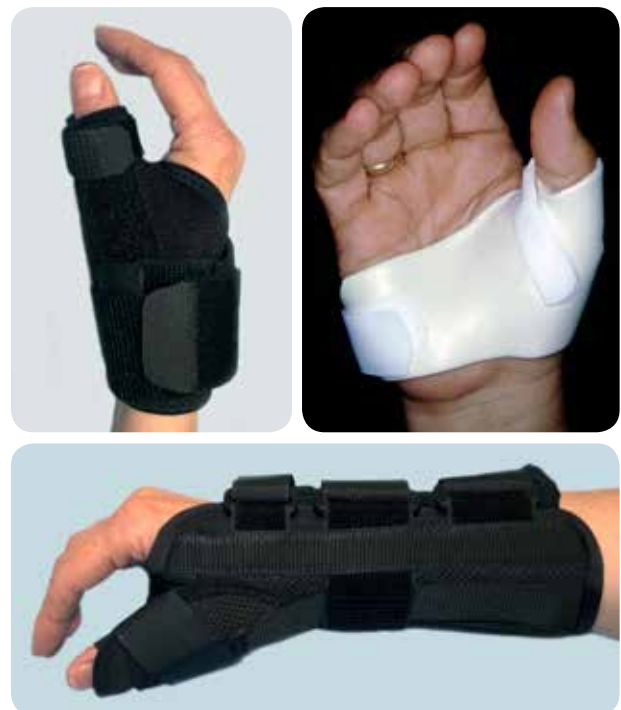

Figure 4: Examples of custom and commercial brace designs for the thumb CMC joint.

in stabilizing muscle strength is likely a contributing factor to the progression of the pathological imbalance at the joint.

Motion, joint loading, and muscle strengthening have been shown to improve joint stability in patients with OA in large joints.^{30,31} Although data for small non-weight-bearing joints is lacking, recent publications on the treatment of thumb CMC OA suggest exercises and bracing facilitate pain control and use of the thumb in a balanced manner.^{13,24,25,32-38}

The challenge of treating thumb CMC joint osteoarthritis is to balance the opposing goals of providing both stability and mobility to the thumb CMC joint.

often worn only at night, and normal daily activities continue without bracing support.²¹ Consequently the dynamic force imbalance that encourages thumb CMC joint deformity continues to influence pathological progression during the day.⁴⁰

DESIGNING THE IDEAL BRACE

An ideal brace would stabilize *only* the thumb CMC joint, controlling pain by preventing dorsal translation of the metacarpal base. The brace would also encourage a balanced posture of the thumb while allowing maximum function so that it could be worn during nearly

An ideal brace would stabilize only the thumb CMC joint, controlling pain by preventing dorsal translation of the metacarpal base.

all activities. Maintaining ideal joint alignment during thumb muscle contraction may increase function, decrease pain, and potentially may slow or control the deformity progression.^{19,22,33,41,42}

Customary immobilization brace designs use three points of pressure to prevent joint motion in all directions. Since the CMC joint cannot be completely surrounded, it is not possible to apply the three-point design just at the CMC joint. Thus, most thumb CMC joint brace designs include adjacent joints, as mentioned above. Since CMC joint osteoarthritis is typically limited to the CMC joint, the ideal thumb brace design need not restrict other joints.

A DIFFERENT DESIGN APPROACH:

USE OF A PSEUDO-HYDRAULIC ENVIRONMENT

Two factors dictate the design of an ideal brace:

1. Joints adjacent to the thumb CMC joint must be excluded to maximize function when wearing the brace; thus a design using three points of pressure cannot be used.
2. The brace must specifically prevent CMC dorsal translation.

The Push ortho Thumb Brace CMC developed by Nea International performs these functions through the principles of dynamic stabilization using the pseudo-hydraulic environment. Originally developed in the mid-20th century as a way to stabilize long bones during fracture healing, a pseudo-hydraulic environment uses pressure created by contracting muscles within a closed cylinder to stabilize the bone encircled by the muscles.⁴³

The Push ortho Thumb Brace CMC stabilizes the thumb metacarpal by firmly encircling the thenar muscles so that the internal pressure created by the contraction of these muscles will create a pseudo-hydraulic environment. With the first metacarpal stabilized, dorsal translation at the CMC joint is minimized. When a well-fitting brace is in place, the very muscle contraction which normally causes the base of the first metacarpal to translate dorsally on the trapezium will, instead, stabilize the base of the metacarpal. This phenomenon is called *dynamic stabilization*.

In contrast to an immobilization design, this brace using the pseudo-hydraulic principle allows some motion within the "cylinder." As the muscles enlarge during muscle contraction, they fill the snugly-fitting cylinder, creating internal pressure within the confines of the brace which stabilizes the metacarpal (Figure 5). The brace does not need to cover the joint to provide this stability; it only needs to cover and encase the thenar muscles.

Those expecting traditional immobilization from the Push ortho Thumb Brace CMC are surprised by the extent of thumb mobility possible while wearing the brace. Thumb CMC motion is possible within the middle range while wearing the

brace, but when the thenar muscles contract in response to an external load, the muscle contraction stabilizes the first metacarpal and movement is restricted.

The Push ortho Thumb Brace CMC uniquely provides the most support when it is needed the most - during active use of the thumb.

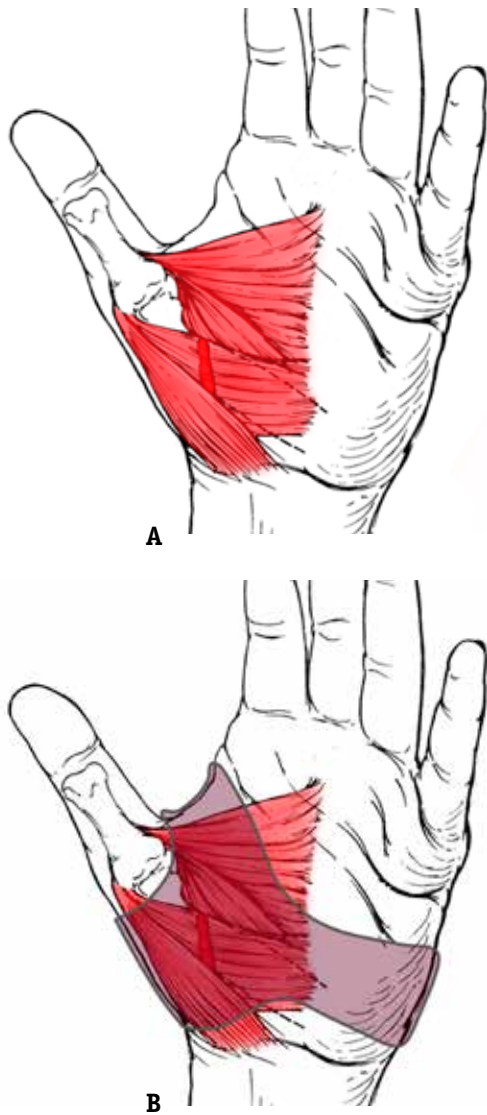


Figure 5: A) The thenar muscles (the flexor pollicis brevis is cut away to show the underlying opponens pollicis) which enlarge when they contract. B) The Push ortho Thumb Brace CMC encircles these muscles, creating stabilizing internal pressure when the muscles contract.

Although the Push ortho Thumb Brace CMC restricts end-range thumb CMC joint motion (flexion, extension, abduction and adduction), it is the restriction of dorsal translation at the CMC joint that is the essential role of the brace. The Push ortho Thumb Brace CMC thus uniquely provides the most support when it is needed

The metal insert must be firmly contoured to snugly fit around the thenar muscles.

the most - during active use of the thumb. Consequently, an individual trying on the Push ortho Thumb Brace CMC who does not have thumb osteoarthritis or CMC

joint hypermobility will be unable to experience the restriction of dorsal translation the brace provides.

For dynamic stabilization using the pseudo-hydraulic principle to be effective the brace must precisely and snugly fit the contours and size of the relaxed thenar muscles. As individual thumb sizes and shapes vary, the material encircling the thenar muscles must be adjustable to provide an individual custom fit.

The most important aspect of the Push ortho Thumb Brace CMC is that the metal insert must be firmly contoured to fit snugly around the thenar muscles (Figure 6). If the fit is loose or imprecise, the pseudo-hydraulic environment does not exist. The Push ortho Thumb Brace CMC provides adjustable custom fitting to the thenar muscle area by incorporating a malleable, bi-contoured aluminum reinforcement within the thenar muscle area of the molded brace (Figure 7).

Since symptom severity is influenced by joint loading,⁴⁰ a brace limiting metacarpal translation under load addresses the desired goal. Such a brace will likely be more effective in both alleviating symptoms and in potentially influencing the course of the disease as compared to an immobilization brace that is rarely worn when most needed because its cumbersome design restricts function.

DESIGN ATTRIBUTES

Custom Fit

The Push ortho Thumb Brace CMC is unique in the industry as the only manufactured CMC brace that allows customized fitting to the thenar area. The multi-contoured, bendable aluminum reinforcement encapsulated in the molded plastic of the Push ortho Thumb Brace CMC allows each brace to be specifically conformed around the relaxed thenar muscles of each individual (Figures 6 & 7).

Minimal Dimensions

Since neither wrist motion nor thumb MP joint motion creates pain with isolated thumb CMC joint osteoarthritis, neither joint is included in the Push ortho Thumb Brace CMC.¹ It has been demonstrated that pain control can be achieved with a smaller brace design^{19,20,44} and individuals prefer a short brace that only includes the thumb CMC joint.^{13,20,41} Although some individuals with OA develop associated MP or wrist joint pathology and inclusion of either/both joints may be indicated for those individuals, this is not descriptive of the majority of those with thumb CMC osteoarthritis.

Additionally, since activities requiring pinch are the primary cause of thumb CMC joint symptoms,¹¹ the smaller brace design leaves critical sensory areas free while allowing unimpeded pinching, fingering, handling and gripping activities.

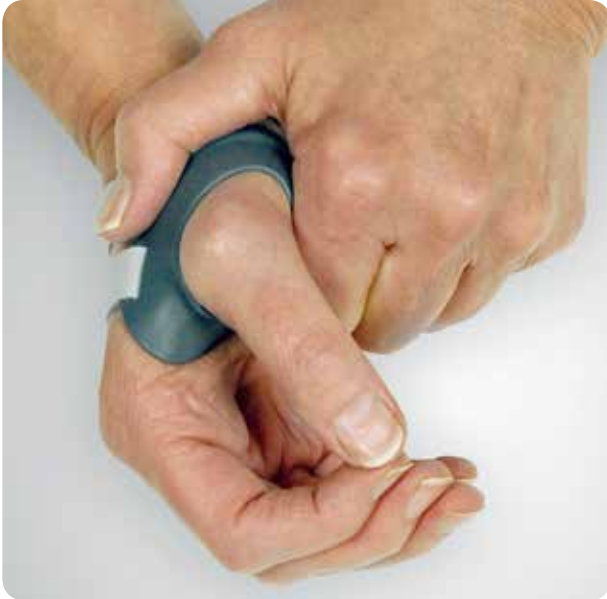

Figure 6: The aluminum insert must be snugly fitted around the thumb muscles.

Muscle Use

Finally, and perhaps most importantly, disuse atrophy of the thenar muscles does not occur because the thenar muscles are actively contracting while in the Push ortho Thumb Brace CMC brace. This is in sharp contrast to immobilization braces which prevent muscle use, thereby weakening the intrinsic thumb muscles.

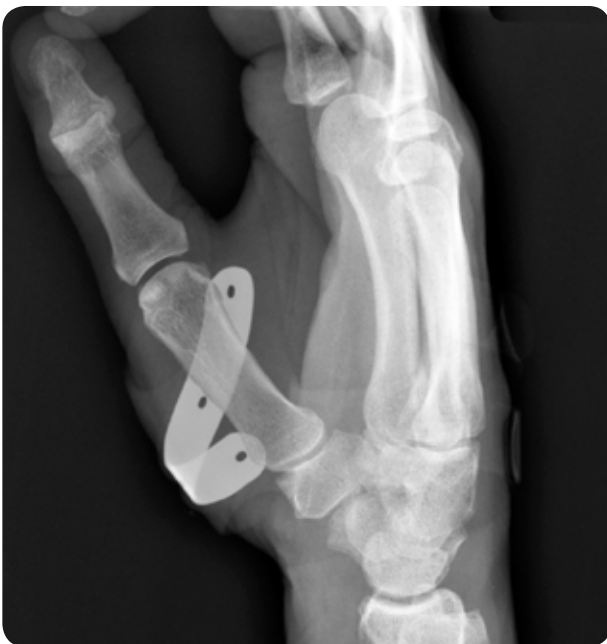

Figure 7: X-ray showing the multi-contoured, bendable aluminum reinforcement surrounding the thenar muscles.

The Push ortho Thumb Brace CMC stabilizes the thumb CMC joint in the ideal mid-position. Repeated active use of the thumb muscles in this posture allows these muscles to maintain their important stabilizing strength. Unlike an immobilization brace, the Push ortho Thumb Brace CMC facilitates balanced use of the stabilizing thumb muscles, increasing the likelihood that brace wear may positively influence the course of the disease. By maintaining a balanced posture when under load, the patient can potentially retrain the thumb muscles to allow weaning from the brace over time.

INDICATIONS FOR USE OF THE PUSH ORTHO THUMB BRACE CMC

Although the Push ortho Thumb Brace CMC was designed to specifically limit dorsal translation of the first metacarpal on the trapezium, the increased stability the brace provides makes it suitable for other clinical applications requiring stabilization of the thumb CMC joint.

Post-Surgery Use

Because the Push ortho Thumb Brace CMC brace allows muscle contraction while thumb CMC joint motion is restricted to the mid zone, it is the ideal post-operative brace following thumb CMC joint reconstruction. The goal of surgical reconstruction of the thumb CMC joint is to re-create stability while still allowing functional mobility. The Push ortho Thumb Brace CMC allows mid-range mobility while protecting the healing capsule from the stress of end range motion. Within the brace the patient actively contracts the thumb stabilizing muscles which strengthens them. This prepares the thumb for functional use in that same mid-position when the brace is discontinued.

The brace can be fitted following removal of the surgical dressing when the wound is stable. The patient can immediately use the hand for light activities while still protecting the healing CMC joint capsule. Unlike braces that immobilize the joint, the Push brace prepares the individual for effective weaning from external support by facilitating muscle strengthening while simultaneously protecting healing tissues.

Thumb CMC Joint Hypermobility

Given the degree of motion the relatively lax ligaments allow at the normal thumb CMC joint, individuals with joint hypermobility often experience excessive motion

The stability the brace provides makes it suitable for other clinical applications.

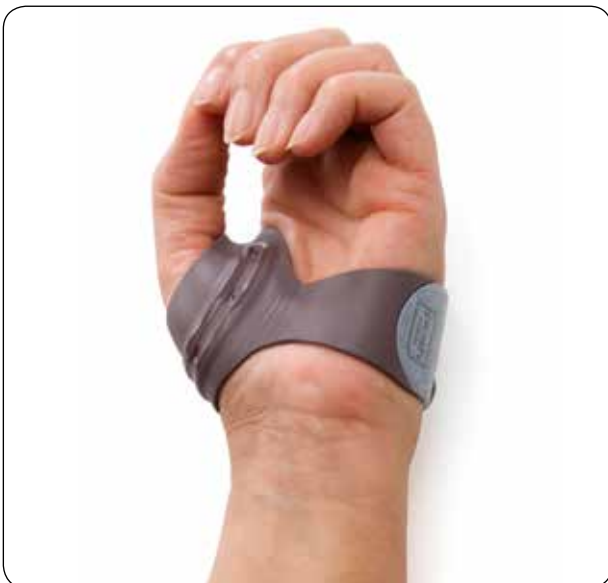
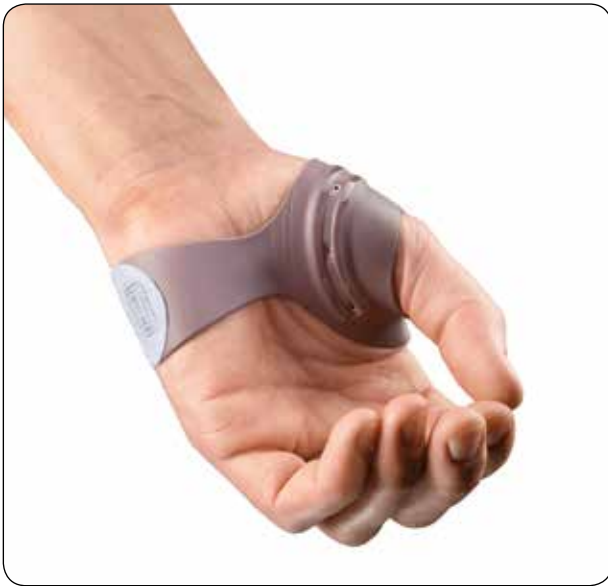
Figure 8: The Push ortho Thumb Brace CMC thumb CMC brace covers minimal area.

at this joint, rendering it unstable during loading. Sometimes these hypermobile joints are symptomatic. Even if pain free, the use of the Push ortho Thumb Brace CMC to stabilize the joint while under load enhances the ability of the thumb to hold and manipulate objects.

The brace has been used successfully by individuals with general hypermobility as well as those with excessive hypermobility such as Erlos Danlos Syndrome.

CAN A SMALL BRACE BE EFFECTIVE?

As stated above, most braces endeavor to immobilize the thumb CMC joint and thus usually include the MP joint and may also include the wrist joint. Because of this design expectation, those who encounter the minimal design of the Push ortho Thumb Brace CMC brace (Figure 8) question whether a small brace can be effective.

Currently there is no research which supports the choice of one thumb CMC brace design to best provide pain relief, patient comfort, and function.⁴⁵ Most studies have investigated patient compliance and pain relief using a variety of braces. These studies have concluded that patients prefer a smaller brace and that smaller braces can provide pain relief.^{17,18,20,39,46-50}

Stability Testing

A recent study by Hamann et al correlated the joint restriction provided and the function allowed by four braces, including the Push ortho Thumb Brace CMC.⁴⁵ Of the four manufactured thumb CMC braces evaluated, the Push ortho Thumb Brace CMC was the only brace that allowed unrestricted motion of both the wrist and the MP joint; the other three restricted the MP joint while two also limited wrist motion.

Motion in three directions (flexion/extension, abduction/adduction and rotation) of both the CMC and the MP joints of eighteen subjects was recorded without bracing and while wearing each of the four braces. The Push ortho Thumb Brace CMC, as well as all other braces, significantly restricted thumb CMC joint motion in all directions, with the Push ortho Thumb Brace CMC retaining the largest range of motion. As would be expected, the Push brace was the only brace studied which did not significantly restrict MP joint motion in at least one direction.

**The Push ortho
Thumb Brace CMC
significantly
restricted thumb
CMC joint motion in
all directions.**

It should be noted that this study used CMC joint range of motion while braced as the assumed predictor of joint stability under load, i.e. management of pain with use. While this is a valid assumption for braces endeavoring to immobilize the CMC joint, the design of the Push ortho Thumb Brace CMC employs dynamic stabilization, not immobilization, to provide joint stability. Since this study did not specifically examine stability

under load, one must question whether the study fully evaluated the dynamic stabilization properties the Push ortho Thumb Brace CMC endeavors to provide. Unlike immobilization braces, the benefit of the pseudo-hydraulic support during pinch and grip is a crucial element of the stability offered by the Push brace.

The Push ortho Thumb Brace CMC had the highest functional score.

under load, one must question whether the study fully evaluated the dynamic stabilization properties the Push ortho Thumb Brace CMC endeavors to provide. Unlike immobilization braces, the benefit of the pseudo-hydraulic support during pinch and grip is a crucial element of the stability offered by the Push brace.

Testing for Function

Although there was no specific test of stability under load, subjects in the Hamann study also completed the Sollerman Hand Function Test for twenty standardized activities of daily living. The Push ortho Thumb Brace

CMC had a significantly higher functional score than the other three braces in the study. Furthermore, the authors found a strong positive correlation of the functional hand scores to the range of motion allowed at both the CMC and MP joints.⁴⁵

ACHIEVING THE IMPOSSIBLE: JOINT STABILITY AND MOBILITY

Successful bracing of the thumb CMC joint must control pain through effective joint stabilization while at the same time maximizing functional mobility. The unique design of the Push ortho Thumb Brace CMC allows maximum mobility of the thumb CMC joint while also providing stability at the joint when the thumb is under load and the thenar muscles are actively contracting. Since the release of the Push ortho Thumb Brace CMC in 2010, many patients with thumb CMC osteoarthritis have reported wearing the Push ortho Thumb Brace CMC for pain control during a wide range of vocational and avocational activities (Figure 9), suggesting that the Push ortho Thumb Brace CMC uniquely meets the contradictory goal of providing both mobility and stability of the thumb CMC joint.



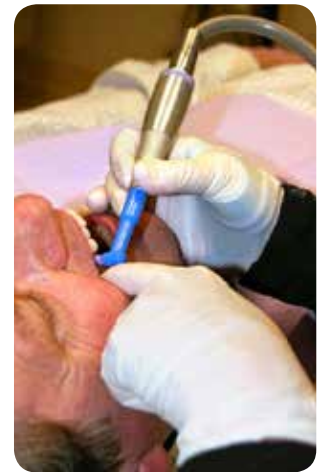
Golfing



Pruning



Quilting



Cleaning teeth



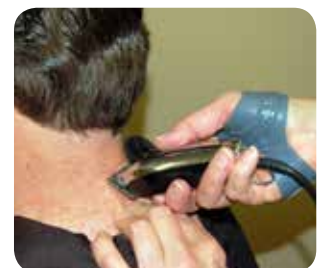Cutting with scissors



Shoeing a horse



Knitting



Haircutting

Figure 9: Examples of vocational and avocational activities while wearing the Push ortho Thumb Brace CMC.

REFERENCES

1. Pai S, Talwalkar S, Hayton M. Presentation and management of arthritis affecting the trapezio-metacarpal joint. *Acta Ortho Belg* 2006;72:3-10.
2. Barron O, Glickel S, Eaton R. Basal joint arthritis of the thumb. *J Am Acad Orthop Surg* 2000;8:314-23.
3. Dias R, Chandrasenan V, Burke F. Basal thumb arthritis. *Postgrad Med J* 2007;83:40-3.
4. Zhang Y, Niu J, Kelly-Hayes M, et al. Prevalence of symptomatic hand osteoarthritis and its impact on functional status among the elderly: The Framingham Study. *Am J Epidemiol* 2002;156:1021-7.
5. Van Heest A, Kallemeier P. Thumb carpal metacarpal arthritis. *J Am Acad Orthop Surg* 2008;16:140-51.
6. Sonne-Holm S, Jacobsen S. Osteoarthritis of the first carpometacarpal joint: a study of radiology and clinical epidemiology. Results from the Copenhagen Osteoarthritis Study. *Osteoarthritis Cartilage* 2006;14:496-500.
7. Swigart C, Eaton R, Glickel S, Johnson C. Splinting in the treatment of arthritis of the first carpometacarpal joint. *J Hand Surg Am* 1999;24:86-91.
8. Armstrong A, Hunter J, Davis, T. The prevalence of degenerative arthritis of the base of the thumb in postmenopausal women. *J Hand Surg Br* 1994;19:340-1.
9. Dahaghin S, Bierma-Zeinstra S, Ginai A, et al. Prevalence and pattern of radiographic hand osteoarthritis and association with pain and disability (the Rotterdam study). *Ann Rheum Dis* 2005;64:682-7.
10. Haara M, Heliövaara M, Kröger H, et al. Osteoarthritis in the carpometacarpal joint of the thumb. Prevalence and associations with disability and mortality. *J Bone Joint Surg Am* 2004;86-A:1452-7.
11. Pellegrini V, Jr. Osteoarthritis at the base of the thumb. *Orthop Clin North Am* 1992;23:83-102.
12. Dillon C, Hirsch R, Rasch E, Gu Q. Symptomatic hand osteoarthritis in the United States: prevalence and functional impairment estimates from the third U.S. National Health and Nutrition Examination Survey, 1991-1994. *Am J Phys Med Rehab* 2007;86:12-21.
13. Kjekken I, Smedslund G, Moe R, et al. Systematic review of design and effects of splints and exercise programs in hand osteoarthritis. *Arthritis Care Res* 2011;63:834-48.
14. Swigart C. Arthritis of the base of the thumb. *Curr Rev Musculoskelet Med* 2008;1:142-6.
15. Murphy N, Dasari B, Adams J. A review of osteoarthritis of the trapeziometacarpal joint (TMJ). *J Rheum Occup Ther* 2009;24:8-11.
16. Zhang W, Doherty M, Leeb B, et al. EULAR evidence based recommendations for the management of hand osteoarthritis: report of Task Force of the EULAR Standing Committee for International Clinical Studies Including Therapeutics (ESCISIT). *Ann Rheum Dis* 2007;66:377-88.
17. Boustedt C, Nordenskiöld U, Lundgren Nilsson A. Effects of a hand-joint protection programme with an addition of splinting and exercise: one year follow-up. *Clin Rheumatol* 2009;28:793-9.
18. Berggren M, Joost-Davidsson A, Lindstrand J, et al. Reduction in the need for operation after conservative treatment of osteoarthritis of the first carpometacarpal joint: a seven year prospective study. *Scand J Plast Reconstr Surg Hand Surg* 2001;35:415-7.
19. Weiss S, LaStayo P, Mills A, Bramlet D. Prospective analysis of splinting the first carpometacarpal joint: an objective, subjective and radiographic assessment. *J Hand Ther* 2000;13:218-26.
20. Weiss S, LaStayo P, Mills A, Bramlet D. Splinting the degenerative basal joint: Custom-made or prefabricated neoprene? *J Hand Ther* 2004;17:401-6.
21. Rannou F, Dimet J, Boutron I, et al. Splint for base-of-thumb osteoarthritis: a randomized trial. *Annals Intern Med* 2009;150:661-9.
22. Wajon A. Clinical splinting successes: the thumb "strap splint" for dynamic instability of the trapeziometacarpal joint. *J Hand Ther* 2000;13:236-7.
23. Gomes Carreira A, Jones A, Natour J. Assessment of the effectiveness of a functional splint for osteoarthritis of the trapeziometacarpal joint of the dominant hand: a randomized controlled study. *J Rehabil Med* 2010;42:469-74.
24. Valdes K, Marik T. A systematic review of conservative interventions for osteoarthritis of the hand. *J Hand Ther* 2010;23:334-50.
25. O'Brien V, McGaha J. Current practice patterns in conservative thumb CMC joint care: survey results. *J Hand Ther* 2014;27:14-22.
26. National Collaborating Centre for Chronic Conditions (UK). Osteoarthritis: national clinical guideline for care and management in adults. London: Royal College of Physicians, 2008.
27. Egan M, Brousseau L. Splinting for osteoarthritis of the carpometacarpal joint: review of the evidence. *Am J Occup Ther* 2007;61:70-8.

28. Pellegrini V, Jr. The basal articulations of the thumb: pain, instability, and osteoarthritis. In: Peimer CA, ed. *Surgery of the hand and upper extremity*. New York: McGraw-Hill; 1996:1019-42.
29. Sokolove J, Lepus C. Role of inflammation in the pathogenesis of osteoarthritis: latest findings and interpretation. *Ther Adv Musculoskelet Dis* 2013;5:77-94.
30. Fransen M, McConnell S, Harmer A, et al. Exercise for osteoarthritis of the knee: a Cochrane systematic review. *Br J Sports Med* 2015;49:1554-7.
31. Alkatan M, Baker J, Machin D, et al. Improved function and reduced pain after swimming and cycling training in patients with osteoarthritis. *J Rheumatol* 2016;43:666-72.
32. Lockard M. Exercise for the patient with upper quadrant osteoarthritis. *J Hand Ther* 2000;13:175-83.
33. Taylor J. Restoration of dynamic stability in early osteoarthritis of the carpometacarpal joint of the thumb. *Hand Ther* 2000;5:37-41.
34. Neumann D, Bielefeld T. The carpometacarpal joint of the thumb: stability, deformity, and therapeutic intervention. *J Orthop Sports Phys Ther* 2003;33:386-98.
35. Moran M. Osteoarthritis and occupational therapy intervention. *Phys Med Rehab: State of the Art Reviews* 2001;15:65-81.
36. O'Brien V, Giveans M. Effects of dynamic stability approach in conservative intervention of the carpometacarpal joint of the thumb: A retrospective study. *J Hand Ther* 2013;26:44-51.
37. Valdes K, von der Heyde R. An exercise program for carpometacarpal osteoarthritis based on biomechanical principles. *J Hand Ther* 2012;25:251-62.
38. Ye L, Kalichman L, Spittle A, et al. Effects of rehabilitative intervention on pain, function, and physical impairment in people with hand osteoarthritis: a systematic review. *Arthritis Res Ther* 2011;13:R28.
39. Wajon A, Ada L. No difference between two splint and exercise regimens for people with osteoarthritis of the thumb: A randomised controlled trial. *Aust J Physiother* 2005;51:245-9.
40. Segal R, Avrahami E, Lebdinski E, et al. The impact of hemiparalysis on the expression of osteoarthritis. *Arthritis Rheum* 1998;41:2249-56.
41. McKee P, Eason-Klatt M. Multi-center study comparing two styles of orthoses for individuals with thumb carpometacarpal osteoarthritis [abstract]. *J Hand Ther* 2006;19:446-7.
42. Colditz J. The biomechanics of a thumb CMC immobilization splint: design and fitting. *J Hand Ther* 2000;13:228-35.
43. Sarmiento A, Kinman P, Galvin E, et al. Functional bracing of fractures of the shaft of the humerus. *J Bone Joint Surg Am* 1977;59:596-601.
44. Colditz J. Anatomic considerations for splinting the thumb. In: Mackin EJ, Callahan A, Skirven T, Schneider LH, Osterman AL, eds. *Rehabilitation of the hand*. 5 ed. St. Louis: Mosby; 2002:1858-74.
45. Hamann N, Heidemann J, Heinrich K, et al. Stabilization effectiveness and functionality of different thumb orthoses in female patients with first carpometacarpal joint osteoarthritis. *Clin Biomech* 2014;29:1170-6.
46. Bani M, Arazpour M, Kashani R, et al. Comparison of custom-made and prefabricated neoprene splinting in patients with first carpometacarpal joint osteoarthritis. *Disabil Rehabil Assist Technol* 2013;8:232-7.
47. Bani M, Arazpour M, Kashani R, et al. The effect of custom-made splints in patients with the first carpometacarpal joint osteoarthritis. *Prosthet Orthot Int* 2013;37:139-44.
48. Becker S, Bot A, Curley S, et al. A prospective randomized comparison of neoprene vs thermoplast hand-based thumb spica splinting for trapeziometacarpal arthrosis. *Osteoarthritis Cartilage* 2013;21:668-75.
49. Gomes Carreira A, Jones A, Natour J. Assessment of the effectiveness of a functional splint for osteoarthritis of the trapeziometacarpal joint on the dominant hand: a randomized controlled study. *J Rehabil Med* 2010;42:469-74.
50. Wilder F, Barrett J, Farina E. Joint-specific prevalence of osteoarthritis of the hand. *Osteoarthritis Cartilage* 2006;14:953-7.

